

Chinese semantic processing cerebral areas

SHAN Baoci¹, ZHANG Wutian², MA Lin³, LI Dejun³, CAO Bingli⁴, TANG Yiyuan⁵, WU Yigen¹ & TANG Xiaowei^{1,4}

1. Institute of High Energy Physics and Laboratory of Nuclear Analysis Techniques, Chinese Academy of Sciences, Beijing 100039, China;
2. Institute of Psychology, Chinese Academy of Sciences, Beijing 100101, China;
3. MRI Center of PLA General Hospital, Beijing 100853, China;
4. Physics Department, Zhejiang University, Hangzhou 310027, China;
5. Institute of Neuroinformatics, Dalian University of Technology, Dalian 116023, China
Correspondence should be addressed to Tang Xiaowei (e-mail: shanbc@mail.ihep.ac.cn)

Abstract This study has identified the active cerebral areas of normal Chinese that are associated with Chinese semantic processing using functional brain imaging. According to the traditional cognitive theory, semantic processing is not particularly associated with or affected by input modality. The functional brain imaging experiments were conducted to identify the common active areas of two modalities when subjects perform Chinese semantic tasks through reading and listening respectively. The result has shown that the common active areas include left inferior frontal gyrus (BA 44/45), left posterior inferior temporal gyrus (BA37); the joint area of inferior parietal lobules (BA40) and superior temporal gyrus, the ventral occipital areas and cerebella of both hemispheres. It gives important clue to further discerning the roles of different cerebral areas in Chinese semantic processing.

Keywords: Chinese cognition, semantic processing, cerebral, cerebellum, functional brain imaging.

DOI: 10.1360/03wc0286

Language plays an important role in the people's intercommunication. Reading and listening are the main approaches to achieve language information. Though the two modalities provide different kinds of information, we can get the same meaning by reading and by listening. It has been the crucial question for cognitive neuroscience to answer how human brain understands language and which parts of the brain take part in language processing. Identifying the semantic processing cerebral areas is important not only in cognitive theory, but in clinic practice as well. For example, the important brain areas, such as speech center, should be kept away in neurosurgery surgery.

Previous knowledge about lingual areas of brain came primarily from the studies on brain-injured patients with language impairment. The lingual areas can be determined according to the injured loci and symptom of language impairment. However, language processing is a complex neural process that is associated with several

brain areas. The single patient may be damaged only one of these areas or the connecting part of two areas, so it can only provide partial information we wanted. Thus it needs many variety cases to determine the lingual areas according to the language impairment of patients. But it is difficult to find the appropriate cases. Functional neuroimaging has been an important method to study human brain function. It has been used in many studies on language processing. Semantic processing is one of the most popular tasks in these studies. According to the widely adopted view of cognition, there exists a semantic-processing network in the brain that is independent of input or output modalities. So finding out the common active areas by directly comparing the cerebral areas activated by visual and auditory semantic tasks is an appropriate method to identify the semantic processing areas. However, only a few studies conducted simultaneously visual and auditory experiments^[1,2], most previous studies employed visual or auditory semantic processing tasks. And what's more, the results of these studies are not fully consistent.

Chinese character as an ideographical writing system may differ from alphabets^[3] in processing. Studies on Chinese semantic processing may extend our knowledge about semantic processing. In recent years, there have been some studies on Chinese neuroimaging^[4-9]. But most of these studies only used visual stimuli. As far as we have known, there was not any study on functional neuroimaging of Chinese semantic processing to use visual and auditory stimuli simultaneously. According to the traditional cognitive theory, semantic processing is not particularly associated with or affected by input modality. Our study will identify Chinese semantic processing areas with the method of searching the common areas activated by visual and auditory semantic processing using fMRI.

1 Methods

Nine right-handed healthy Chinese (6 male and 3 female, age range: 24—37 years old) participated in this study. All subjects speak mandarin and at least have a college level education. There are many homophones in Chinese. In order to avoid the affect of homophone, this study used double-character Chinese words as materials. All the used Chinese words were common words with a frequency of occurrence no less than 34 per million according to the Modern Chinese Frequency Dictionary. Because there is category-specific effect in semantic processing^[10], the animal nouns were used as materials in this study. The experimental paradigm was block-design, which consisted of two sessions, one was for visual stimuli, and the other for auditory stimuli. The visual and auditory stimuli were delivered in separate sessions. There were in total 4 task blocks (40 s) and 4 control blocks (20 s) in each session, task and control were alternated and began with control. In the visual session, the words were shown through a projector system connected with a PC-computer, which

REPORTS

controlled the appearing sequence and lasting time of each word. Each word lasted 2 s. The subjects were asked to fixate on “+” at the center of visual field in the control blocks, and to make no judgment. Whereas, in the task blocks, the subjects were asked to judge whether or not the words delivered were animal names. Subjects were asked to press right hand button if the word was an animal name, and press left hand button if not. The reaction accuracy data were recorded using a custom-made magnet-compatible key-press system. If the accuracy was lower than 80%, the data were eliminated. Each task block included 10 animal words and 10 non-animal words, which were presented randomly. In the auditory session, the experimental paradigm was similar to that in visual session, except that the subjects did not listen to any material in control block. The auditory materials were digitized at a normal speaking rate by a PC computer, and were delivered through a modified headphone connected to an MR-compatible sound transducer.

Images were acquired on a 1.5T GE signa magnetic resonance imaging system. Blood oxygen level-dependent (BOLD) images were acquired using a T_2^* -weighted echo planar imaging (EPI) sequence, with TR=2 s and TE=40 ms. To cover the whole brain, there were 14 slices, each was 7 mm thick with 1 mm gap between them. The acquisition matrix was 64×64×14. In order to avoid the T1 effect, stimuli were presented after the functional image scanned for 8 s. The first four images were deleted when data were analyzed. Every session lasted 4 min, 120 functional images of entire brain were acquired. The functional image data were analyzed using SPM99 software (the Wellcom Department of Cognitive Neurology, Institute of Neurology, London, UK). The image data were transformed into the Analyze format used by SPM99 using in-house software. Spatial realignment was performed prior to further analysis. The realigned image sequences were spatially normalized to stereotaxic atlas space of Talairach^[11], and then the normalized images were spatially smoothed with Gaussian kernel of 12 mm×12 mm×24 mm (FWHM). The statistical analysis on the smoothed time series images was based on the general linear model (GLM). Global effects were removed using proportional scaling. A high-pass filter and a low-pass filter were used to remove the measurement noise and physiological noise. Significant changes of task comparing with control were accessed using one-tail t-statistics. The t-ratios were estimated for each voxel in the image and formed the statistical parametric maps which showed activation above the uncorrected height threshold $P<0.01$. Finally, the common brain areas activated jointly by visual and auditory sessions were identified using Mask function of SPM^[10].

2 Results

The common significant areas of activation are summarized in Table 1, which include left inferior frontal

gyrus (BA44/47), the joint area of left inferior parietal lobules (BA40) and posterior superior temporal gyrus (BA22), joint area of left fusiform gyrus (BA37) and ventral occipital areas (BA18/19), the joint areas among right inferior parietal lobules (BA40) and posterior superior temporal gyrus (BA22) and postcentral gyrus (BA1/2/3), right ventral occipital areas (BA18/19), and the cerebella of both hemispheres. These active areas are overlaid on the 3-dimensional structure image in color mode as shown in Fig. 1.

Table 1 The common areas activated by visual and auditory Chinese semantic processing

Common areas	BA Talairach coordinate (x,y,z)				T value
Prefrontal					
L inferior prefrontal gyrus	44	-52	14	12	5.03
R inferior prefrontal gyrus	47	-52	30	-2	3.31
Parietal					
L inferior parietal lobules	40	-46	-38	34	3.24
R inferior parietal lobules	40	66	-20	14	3.57
Temporal					
L fusiform	37	-46	-54	-16	4.26
L superior temporal gyrus	22	-54	-24	12	2.43
R transverse temporal gyrus	42	68	-20	12	3.50
Occipital					
L ventral occipital areas	18	-22	-98	6	13.20
R ventral occipital areas	18	22	-98	2	12.30
Cerebella					
L cerebella		-44	-64	-22	10.78
R cerebella		44	-64	-22	9.68

$P=0.01$; BA, Brodmann areas.

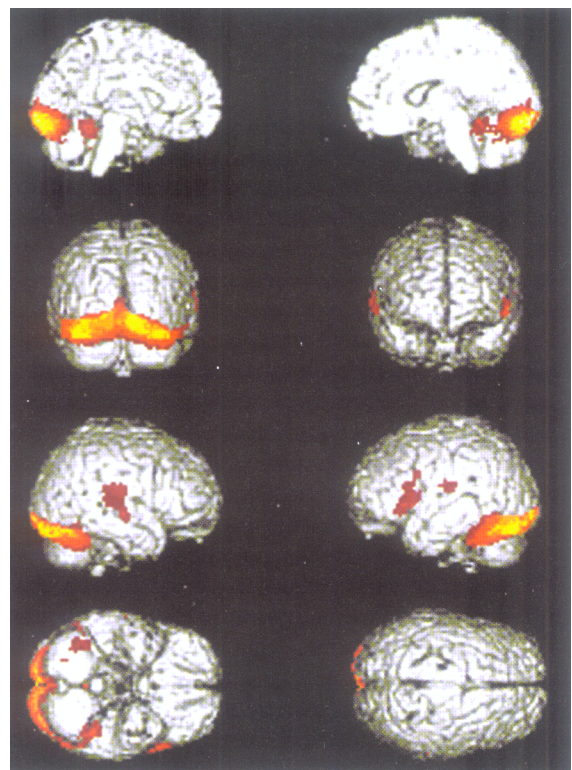


Fig. 1. The common active areas overlaid on the 3-dimensional structure image in color mode.

3 Discussions

The most active areas of this study were consistent with the results of former studies. In these common active areas, left inferior frontal gyrus (BA44/47) was the classic lingual area, Broca's area and its adjacent area. The studies on brain damage^[12] and functional neuroimaging^[8,10] have all indicated that these areas were closely related to language-processing although there exist different opinions on its function in language processing. The left inferior frontal gyrus was traditionally believed to have "expressive" or "output" functions. This kind of view mainly came from the studies on brain injured patients, because damage of this area (main part at Broca's area) will cause ataxic aphasia. However, our study and several other reports^[4,6-8] found the activation of left inferior frontal gyrus under the condition of none of speech production. Recently, some researchers have suggested that it serves as "execute" function, such as choosing, comparing, judging and retrieving^[13].

The left posterior superior temporal gyrus and its adjacent area was another common active area, which was the second traditional language area, Wernicker area. Previous studies have shown that the damage of this area will bring sensory aphasia. In recent years, many functional neuroimaging experiments have revealed that this area plays an important role in semantic processing^[14,15], it is activated not only by visual semantic task^[16] but also by auditory semantic task^[17]. In addition, this area was commonly activated in the visual and auditory functional neuroimaging experiment^[9].

The left posterior inferior temporal gyrus and its adjacent areas, fusiform gyrus and inferior occipital areas, were frequently mentioned in the recent language experiments. The study on brain injured patients showed that left posterior inferior temporal gyrus is related to semantic impairment^[18]. Price et al.^[19] indicated that this area was a crucial area for semantic processing. Recent experiments of functional neuroimaging^[20,21] and ERP^[22] have also indicated that this area is probably related to semantic processing, because it was activated by visual semantic processing task^[15,23,24], auditory semantic processing task^[10], and picture semantic cognition task^[25]. In the visual and auditory language experiments, Booth et al.^[2] found that this area and adjacent left posterior middle temporal gyrus were activated. They suggested that these areas were responsible for semantic processing. Left posterior inferior temporal gyrus and its adjacent areas was an important area not only for English and other alphabetic language processing, but also for Chinese processing^[2,3]. In addition, fusiform gyrus has strong relativity with parietal-temporal area^[26]. The left posterior inferior temporal gyrus and its adjacent areas were called the third language area following "Broca area" and "Wernicker area"^[27].

The activation of right supramarginal gyrus and pos-

terior temporal lobe is consistent with the result of former functional neuroimaging study on Chinese processing^[4-6]. However, the activation of this area is seldom found in semantic processing experiments of English and other alphabetic languages. It needs to be further verified if this area is a specific Chinese processing area.

The activation of cerebellum was also found in the other studies on the Chinese^[5-7] and other language^[6,8] processing. Now, the view that cerebellum was concerned with cognition has been accepted. But the function of cerebellum was still not clear in language processing. It was considered to serve as assistant function in semantic processing^[7]. Considering that there were both semantic processing and action of pressing button in our experiment, we could not judge that either semantic processing or action of pressing button activated cerebellum.

The activation of the ventral part of occipital lobe (BA18/19) was not predicted. It was reasonable that these areas were activated by visual task, but the reason for these areas activated by auditory task was not very clear. We inferred that this was the result of subjects imaging the word form when they heard a Chinese word. Previous study has found that the ventral part of occipital lobe is related to imaging^[28], so we guess that the activation of this area is not caused by semantic processing. It needs further exploring why this area is activated by auditory semantic processing.

Acknowledgements This work was supported by the National Basic Research Program of China (Grant No. G1999054000).

References

1. Chee, M., O'Craven, K. M., Bergida, R. et al., Auditory and visual word processing studied with fMRI, *Human Brain Mapping*, 1999, 7: 15—28.
2. Booth, J. R., Burman, D. D., Meyer, J. R. et al., Modality independence of word comprehension, *Human Brain Mapping*, 2002, 16: 251—261.
3. Rozin, P., Poritsky, S., Sotsky, R., American children with reading problems can easily learn to read English represented by Chinese characters, *Science*, 1971, 171: 1264—1267.
4. Chee, M., Tan, E., Thiel, T., Mandarin and English single word processing studied with functional magnetic resonance imaging, *J. Neurosci.*, 1999, 19: 3050—3056.
5. Tan, L. H., Spinks, J. A., Gao, J. H. et al., Brain activation in the processing of Chinese characters and words: A functional MRI study, *Human Brain Mapping*, 2000, 10: 16—27.
6. Tan, L. H., Liu, H. L., Perfetti, C. A. et al., The neural system underlying Chinese logograph reading, *Neuroimage*, 2001, 13: 836—846.
7. Tan, L. H., Feng, C. M., Fox, P. T. et al., An fMRI study with written Chinese, *Neuroreport*, 2001, 12: 83—88.
8. Luck, K. K., Liu, H. L., Wai, Y. Y. et al., Functional anatomy of syntactic and semantic processing in language comprehension, *Human Brain Mapping*, 2002, 16: 133—145.
9. Xiang, H., Lin, C., Ma, X. et al., Involvement of the cerebellum in

- semantic discrimination: An fMRI study, *Human Brain Mapping*, 2003, 18: 208—214.
10. Noppeny, U., Price, C. J., Functional imaging of the semantic system: Retrieval of sensory-experienced and verbally learned knowledge, *Brain and Language*, 2003, 84: 120—133.
 11. Talairach, J., Tournoux, P., *Co-planar Stereotaxic Atlas of the Human Brain*, New York: Thieme, 1988, 1—110.
 12. Swick, D., Role of left inferior prefrontal cortex in retrieval of semantic, *Cognitive Brain Research*, 1998, 7: 143—157.
 13. Cabeza, R., Nyberg, L., Imaging cognition II: An empirical review of 275 PET and fMRI studies, *J. Cogn. Neurosci.*, 2000, 12: 1—47.
 14. Demonet, J., Chollet, F., Ramsay, S. et al., The anatomy of phonological and semantic processing in normal subjects, *Brain*, 1992, 115: 1753—1768.
 15. Grossman, M., Koenig, P., DeVita, C. et al., Neural representation of verb meaning: An fMRI study, *Human Brain Mapping*, 2002, 15: 124—134.
 16. Perani, D., Cappa, S. F., Schnur, T. et al., The neural correlates of verb and noun processing: A PET study, *Brain*, 1999, 122: 2337—2344.
 17. Newman, S. D., Twieg, D., Difference in auditory of words and pseudowords: An fMRI study, *Human Brain Mapping*, 2001, 14: 39—47.
 18. Alexander, M. P., Hiltbrunner, B., Fischer, R. S., Distributed anatomy of transcortical sensory aphasia, *Archives of Neurology*, 1989, 46: 885—892.
 19. Price, C. J., The functional anatomy of word comprehension and production, *Trends in Cognitive Sciences*, 1998, 2: 281—288.
 20. Murtha, S., Chertkow, H., Beauregard, M. et al., The neural substrate of picture naming, *J. Cogn. Neuroscience*, 1999, 11: 399—423.
 21. Buchel, C., Price, C., Friston, K., A multimodal language region in the ventral visual pathway, *Nature*, 1998, 394: 274—276.
 22. Hinojosa, J. A., Martin-Loeches, M., Rubia, F. J., Event-related potentials and semantics: An overview and an integrative proposal, *Brain and Language*, 2001, 78: 128—139.
 23. Devlin, J. T., Russell, R. P., Davis, M. H. et al., Is there an anatomical basis for category-specificity? Semantic memory studies in PET and fMRI, *Neuropsychologia*, 2002, 40: 54—75.
 24. Thompson-Schill, S. L., Aguirre, G. K., D'Esposito, M. et al., A neural basis for category and modality specificity of semantic knowledge, *Neuropsychologia*, 1999, 37: 671—676.
 25. Vandenberghe, R., Price, C., Wise, R. et al., Functional anatomy of a common semantic system for words and pictures, *Nature*, 1996, 383: 254—256.
 26. Horwitz, B., Rumsey, J. M., Donohue, B. C., Functional connectivity of the angular gyrus in normal reading and dyslexia, *Proc. Natl. Acad. Sci. USA*, 1998, 95: 8939—8944.
 27. Luders, H., Lesser, R. P., Hahn, J. et al., Basal temporal language area, *Brain*, 1991, 114: 743—754.
 28. O'Craven, K. M., Kanwisher, N., Mental imagery of faces and places activates corresponding stimulus-specific brain regions, *J. Cogn. Neuroscience*, 2000, 12: 1013—1023.

(Received June 6, 2003; accepted October 9, 2003)